

1

Transoesophageal Echocardiography Safety

HENRY SKINNER

1.1 Indications and contra-indications

- Transoesophageal Echocardiography (TOE) is considered a **standard of care during cardiac surgery**.
 - Europe: TOE in all adult patients undergoing cardiac or thoracic aortic surgery.
 - North America: TOE for all open-heart surgery and to be considered for CABG.
- TOE causes serious injury in <1/1000 examinations.
- TOE-related injury should inform the consent process and serve as a reminder that performing a TOE carries an inherent risk.
- No TOE means no TOE-related damage but to withhold TOE in a patient undergoing cardiac surgery may not be the patient's interest!
- Contra-indications include perforated viscus, significant oesophageal pathology (stricture, trauma, tumour, scleroderma, Mallory-Weiss tear, diverticulum), upper gastrointestinal (GI) bleeding, recent upper GI surgery and oesophagectomy, although safe TOE use in a patient with a previous oesophagectomy has been reported.
- TOE may be considered in patients with gastro-oesophageal disease if the expected benefit outweighs the potential risk, provided appropriate precautions are followed.

1.2 Incidence

There seems to be a higher incidence of injuries in cardiac theatres compared to the echolab; this is because the cardiac surgical patient (asleep and paralysed) cannot react to noxious stimuli or help to swallow the probe, they tend to have more extended examinations and are (probably) more often used for teaching.

COMPLICATION RELATED TO TOE	INCIDENCE
Sore throat	1 in 12
Swallowing dysfunction	1 in 25
Oropharyngeal mucosal injury	1 in 500
Oesophageal perforation and GI bleed	1 in 1250
Dental injury	1 in 3000
Death	1 in 3000

1.3 Mechanism of injury

- Injury follows the path of insertion of the probe all the way from the mouth (lips, teeth and tongue) to the stomach.
- Injury is caused when an excessive force (absolute or relative) is exerted on tissue during probe insertion or manipulation (especially probe flexion with the probe in the oesophagus).
- Tissue necrosis can also be caused by sustained pressure exerted by a static probe in situ.
- When acquiring a Short Axis (SAX) view of the left ventricle (LV), the tip of the probe may actually still be in the oesophagus and there is thus a clear potential for tissue trauma if the probe is ante- or retroflexed when the operator assumes the probe is already within the stomach.

1.4 Risk factors

- Risk factors associated with oesophageal injury are small patient size, female sex, advanced age, prolonged procedure, difficult probe placement, cardiomegaly, low cardiac output, MitraClip® procedure (interventional cardiology) and return to the operating room.
- Many injuries occur in the absence of known risk factors.

1.5 Oesophageal injury

- A ruptured oesophagus carries a mortality of approximately 20%.
- The hall marks of good management include a high index of suspicion, early diagnosis and early surgical intervention.
- Blood in the oropharynx or blood on removal of the TOE probe is an early clue but does not necessarily imply significant injury.
- Inability to visualize cardiac structures during the TOE examination should alert the operator to the possibility that the probe may not be within the oesophagus or stomach.
- Time to presentation is often delayed with diagnosis beyond 24h in more than half of patients.
- Signs of rupture may be subtle and frequently masked by post-operative intubation and sedation.
- Meckler's triad of vomiting, pain, subcutaneous emphysema (signs of spontaneous rupture) is seldom present and the initial chest X-ray (CXR) may be normal (33% in one study). Non-specific signs include dyspnoea, fever, bloody nasogastric (NG) aspirates.
- Literature suggests a low threshold to insert a NG tube if it was difficult to insert the probe or if blood is present on probe removal.
- A contrast oesophagography should be performed to identify the site of perforation as this determines subsequent management.

1.6 Prevention

- Insert the probe by preference with the aid of a video-laryngoscope or under direct vision with the use of a laryngoscope and generous lubrication. This markedly reduces the incidence of swallowing dysfunction and oropharyngeal mucosal injury and helps the operator to stay in the midline.

- If resistance is met, do not force insertion; ask for senior help, ensure the probe is in a neutral position, and realign the probe.
- Never insert or remove the probe in a locked position.
- Direct supervision is advised until the operator is deemed proficient.
- Limit unnecessary probe manipulation.
- If TOE is considered essential/highly desirable in patients with prior oesophageal disease risk, consider referral for an upper GI endoscopy first and consider performing a targeted rather than comprehensive examination.
- Distraction of the anaesthetist by TOE could be detrimental to performing other complex tasks that require a high level of cognitive processing and ideally time should be set aside to perform the TOE prior to commencing surgery.

1.7 References

1. Ramalingam G, et al. *Complications related to peri-operative transoesophageal echocardiography – a one-year prospective national audit by the Association of Cardiothoracic Anaesthesia and Critical Care*. *Anaesthesia* 2020; 75(1):21-26
2. Hilberath JN, et al. *Safety of Transesophageal Echocardiography*. *J Am Soc Echocardiogr* 2010; 23:1115-27.
3. Lennon MJ, et al. *Transesophageal echocardiography-related gastrointestinal complications in cardiac surgical patients*. *J Cardiothorac Vasc Anesth* 2005;19:141-5.

2

TOE Views & Comprehensive Exam

ECKHARD MAUERMANN
MANFRED SEEBERGER

2.1 Aims and Goals

- Goals: qualitative and quantitative assessment of morphology and function of chambers, valves and vessels.
- Aims: to guide and document interdisciplinary management AND to improve patient outcomes.

2.2 Indications

2.2.1 Cardiac and thoracic aortic procedures

- CABG: (aortic and venous cannulation, wall motion, separation from cardiopulmonary bypass (CPB) and haemodynamic management, new findings [such as patent foramen ovale (PFO)], etc.).
- Valve repair/replacement (as above + confirmation of indication, visualization of other surgical steps (e.g. peripheral cannulation, LV vent placement, LV size during cardioplegia, etc.), mechanisms of valve pathology, sizing of valve, assessment of valve repair/replacement, etc.).
- Thoracic procedures (as above + confirmation of indication, assessment of aorta (entry/exit flaps, true/false lumen, wire for direct aortic cannulation), aortic valve (AV), coronary arteries, anastomoses, and reinsertion of coronary buttons, etc.).
- Guiding interventional or non-surgical procedures (MitraClip[®],
- Transapical valves, occluder devices, thrombus assessment prior to cardioversion, etc.).

2.2.2 Noncardiac surgery

- Patient risk factors (severely reduced ventricular function, valve pathologies).
- Intervention (liver surgery, thoracic surgery).
- Unexplained persistent hypotension or hypoxaemia.

2.1 Aims and Goals

- Goals: qualitative and quantitative assessment of morphology and function of chambers, valves and vessels.
- Aims: to guide and document interdisciplinary management AND to improve patient outcomes.

2.2 Indications

2.2.1 Cardiac and thoracic aortic procedures

- CABG: (aortic and venous cannulation, wall motion, separation from cardiopulmonary bypass (CPB) and haemodynamic management, new findings [such as patent foramen ovale (PFO)], etc.).
- Valve repair/replacement (as above + confirmation of indication, visualization of other surgical steps (e.g. peripheral cannulation, LV vent placement, LV size during cardioplegia, etc.), mechanisms of valve pathology, sizing of valve, assessment of valve repair/replacement, etc.).
- Thoracic procedures (as above + confirmation of indication, assessment of aorta (entry/exit flaps, true/false lumen, wire for direct aortic cannulation), aortic valve (AV), coronary arteries, anastomoses, and reinsertion of coronary buttons, etc.).
- Guiding interventional or non-surgical procedures (MitraClip[®],
- Transapical valves, occluder devices, thrombus assessment prior to cardioversion, etc.).

2.2.2 Noncardiac surgery

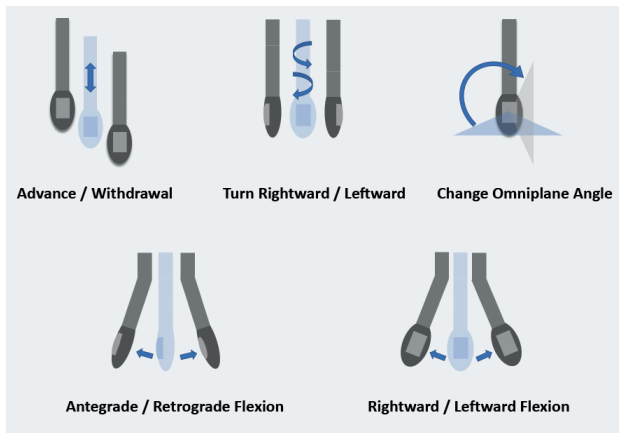
- Patient risk factors (severely reduced ventricular function, valve pathologies).
- Intervention (liver surgery, thoracic surgery).
- Unexplained persistent hypotension or hypoxaemia.

2.2.3 Critical care and emergency department

- Assessment of cardiac function and tamponade.
- Assessment of mechanical support (IABP, Impella®, ECMO).

2.3 Image acquisition

2.3.1 Probe manipulation



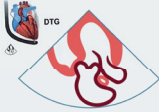
2.3.2 General considerations of image acquisition

- Electrocardiography (ECG) for better understanding of the images (not just for ECG gating).
- Use apnoea when necessary and permissible.
- Optimize the probe to obtain the ideal acoustic window.
 - Always move the probe in only one dimension at a time.
 - Small movements of the probe result in substantial changes of the imaging plane.


- Understand ultrasound image creation and optimize what you want to see.
 - Adjust depth/use zoom/decrease width of the two-dimensional (2D) imaging sector to maximize resolution in the area of interest.
 - Move focus to the area of interest (best lateral resolution).
 - Optimize spatiotemporal resolution (narrow sector to increase frame rate, use of ECG-gating, etc.).
 - Use presets for resolution, general and penetration modes.
- Evaluate images before finalizing acquisition.
- If you get lost, go back to a known structure (e.g. LV at 0°).
- Comfortable positioning for the echocardiographer helps to obtain the best images possible.

2.3.3 TOE 2D scanplanes

DTG – Deep Transgastric

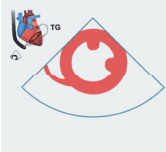

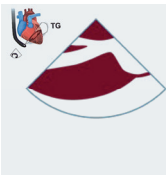

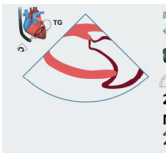

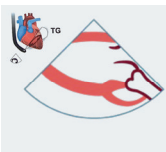

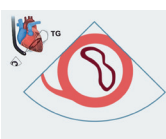



DTG view
45 – 50 cm
Advance deep into stomach and antelex
0°
2D AV, Ao-root evaluation
CFD AV
Doppler AV (AS, AR)

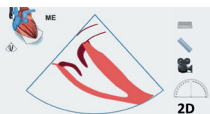


DTG RV-inflow view
45 – 50 cm
Advance deep into stomach and antelex
100 130°
2D AV, Ao-root evaluation
CFD AV
Doppler AV (AS, AR)

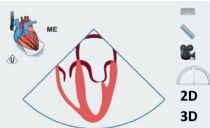
TG – Transgastric

		<p>TG Mid-SAX view 40 – 45 cm Advance probe and anteflex slightly, withdraw from DTG 0° Mid-LV myocardium (function, thickness), pericardium, RV turn right Dimensions (FS), area (FAC), myocardial thickness Biplane to TG 2-chamber view</p>
		<p>TG IVC LAX view 40 – 45 cm Advance probe and anteflex slightly and turn right, withdraw from DTG 30° Liver, hepatic veins, IVC and RA (partial) Dimension and respiratory variation IVC Hepatic vein flow</p>
		<p>TG two chamber view (TG 2C view) 40 – 45 cm Start from TG Mid SAX, anteflex slightly, withdraw for MV 90° LV myocardium (inferior and anterior), papillary muscles, chordae, MV Dimensions (FS), myocardial thickness Biplane to TG mid SAX</p>
		<p>TG LAX view 40 – 45 cm Start from TG Mid SAX, anteflex slightly 120° LVOT, AV LVOT, AV LVOT, AV</p>
		<p>TG basal SAX 40 cm Withdraw from TG Mid SAX, anteflex slightly 0° Basal LV myocardium, MV ('fish mouth') MV</p>

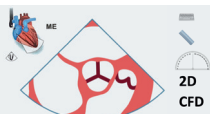ME – Mid-Oesophageal



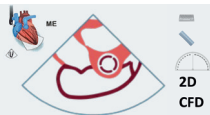ME Coronary sinus view
40 cm
Withdraw from TG basal SAX or advance from ME four chamber view
0°
Coronary sinus for retrograde cardioplegia cannula or CRT-wire



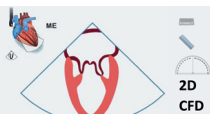ME four chamber view
35 - 40 cm
Withdraw from TG Mid SAX, retroflex
0°
LV function (septal and lateral walls), RV, MV, TV, pericardium
LV, MV, RV, TV
TV, MV
M-mode TAPSE, MAPSE
Doppler Transmitral flow, transtricuspid flow, Tissue Doppler
Biplane to ME two chamber



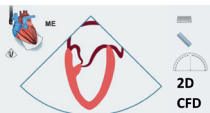ME AV SAX
35 - 40 cm
30° - 40°
2D AV, Coronary arteries
CFD AV, Coronary arteries



ME RV in - outflow
35 - 40 cm
60°
2D TV, TV, PV, RVOT, proximal PA
CFD TV, PV, RVOT



ME bicommissural view
35 - 40 cm
60°
2D MV (P3, A2, P1), (LAA)
CFD MV

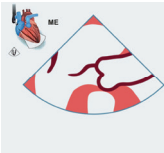


ME two chamber view
35 - 40 cm
90°
2D LV function (inferior and anterior walls), MV, (LAA)
CFD MV
M-mode Biplane to ME four chamber



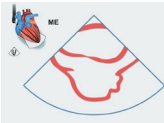
ME LAX view (TG LAX)
35 – 40 cm
120°
LV (Anteroseptal and inferolateral walls), LVOT, AV, MV (P2,A2), LA
MV, LVOT, AV
MV, LVOT

2D
CFD
Doppler



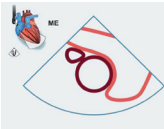
ME AV LAX view (TG AV LAX)
35 – 40 cm
Zoom from ME LAX
120°
MV, AV, Ao root (dimensions)
MV, LVOT, AV
MV, LVOT

2D
CFD
Doppler



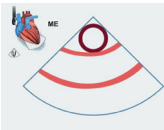
ME bicaval view
35 - 40 cm
110 – 120°
RA, IAS, SVC, <ivc
IAS. (PFO, ASD...)

2D
CFD



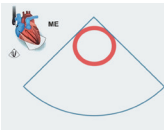
ME asc aortic SAX
30 cm
120°
SVC, Ao, PA
PA
PA

2D
CFD
Doppler



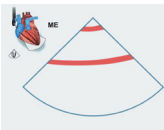
ME asc aortic SAX
30 cm
90°
Ao
Ao
Ao flow reversal

2D
CFD
Doppler



ME asc aortic SAX
35 - 40 cm
0°
Ao
Ao
Ao flow reversal

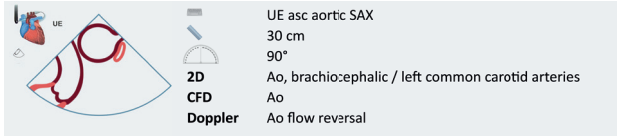
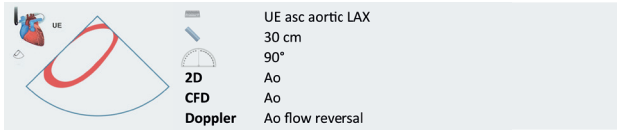
2D
CFD
Doppler



ME asc aortic LAX
35 - 40 cm
90°
Ao
Ao
Ao flow reversal

2D
CFD
Doppler

UE – Upper-Oesophageal



2.3.4 TOE 3D views

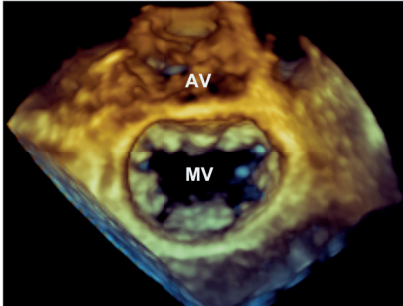
Three-dimensional (3D) images are an integral part of an examination. However, 3D requires optimal 2D image quality, and the cost of 3D is (mainly) temporal resolution. Use ECG-gating when possible and minimize the window (x,y,z).

3D can be used as:

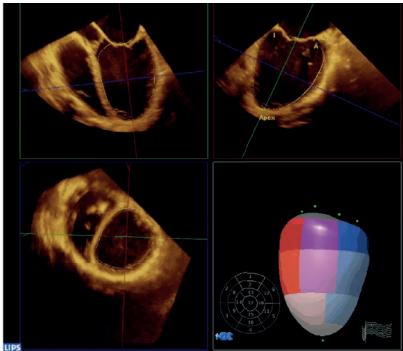
- Live mode (thick slice for visualizing structures and foreign objects).
- Zoom (valves, e.g., measurements left ventricular outflow tract (LVOT) area).
- Colour flow Doppler (CF Doppler) (visualize jets → increase wall filters).
- Full volume (LV and right ventricular (RV) volumes and LV strain/strain rate).

Workflow

- 1/ Optimize the 2D image.
- 2/ Then adjust gain, brightness and smoothing.
- 3/ Crop/rotate to display the 3D image according to guidelines or preferences.



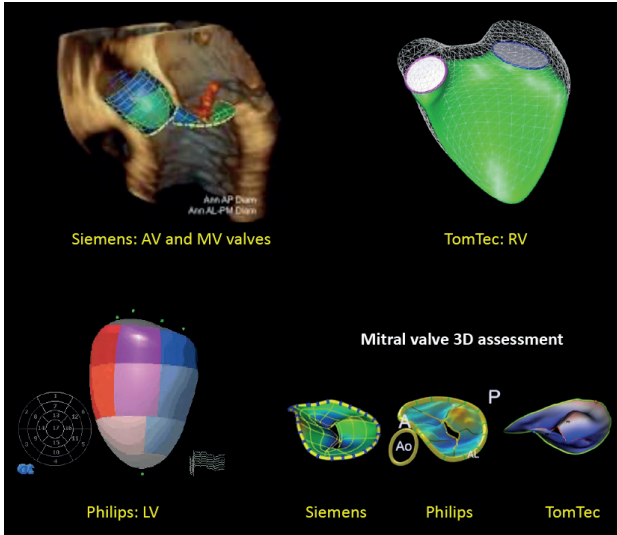
3D Zoom Mitral Valve Surgical view



3D Full Volume of Left Ventricle

A number of **software-based analyses** may be performed. Following acquisition of 3D-datasets, vendor-specific built-in software can be used to perform offline measurements including LV function, mitral and aortic valve assessment. Also, vendor-specific

speckle-tracking based strain and strain rate analyses exist for 2D and 3D. Similarly, dedicated software tools can be applied for the analysis of speckle-tracking based displacement, valve analyses, and RV analyses.



2.4 References

1. Hahn RT, et al. *Guidelines for Performing a Comprehensive Transesophageal Echocardiographic Examination: Recommendations From the American Society of Echocardiography and the Society of Cardiovascular Anesthesiologists*. J Am Soc Echocardiogr. (2013) 26(9):921-64.
2. Kasper J, et al. *Additional Cross-Sectional Transesophageal Echocardiography Views Improve Perioperative Right Heart Assessment*. Anesthesiology. (2012) 117(4):726-34.